

# Treatment of Injuries to the Subaxial Cervical Spine: Recommendations of the Spine Section of the German Society for Orthopaedics and Trauma (DGOU)

Global Spine Journal  
2018, Vol. 8(2S) 25S-33S  
© The Author(s) 2018  
Article reuse guidelines:  
sagepub.com/journals-permissions  
DOI: 10.1177/2192568217745062  
journals.sagepub.com/home/gsj  
SAGE

Philipp Schleicher, Dr med<sup>1</sup>, Philipp Kobbe, Prof Dr med<sup>2</sup>, Frank Kandziora, Prof Dr med<sup>1</sup>, Matti Scholz, Dr med<sup>1</sup>, Andreas Badke, PD Dr med<sup>3</sup>, Florian Brakopp, MD<sup>4</sup>, Helmut Ekkerlein, Dr med<sup>5</sup>, Erol Gercek, Prof Dr med<sup>6</sup>, Rene Hartensuer, PD Dr med<sup>7</sup>, Philipp Hartung, Dr med<sup>8</sup>, Jan-Sven Jarvers, Dr med<sup>9</sup>, Stefan Matschke, Dr med<sup>10</sup>, Robert Morrison, Dr med<sup>11</sup>, Christian W Müller, PD Dr med<sup>12</sup>, Miguel Pishnamaz, Dr med<sup>13</sup>, Maximilian Reinhold, PD Dr med<sup>14</sup>, Gregor Schmeiser, Dr med<sup>15</sup>, Klaus John Schnake, Dr med<sup>16</sup>, Gregor Stein, PD Dr med<sup>17</sup>, Bernhard Ullrich, Dr med<sup>4</sup>, Thomas Weiss, Dr med<sup>18</sup>, and Volker Zimmermann, Dr med<sup>19</sup>

## Abstract

**Study Design:** Expert consensus.

**Objectives:** To establish treatment recommendations for subaxial cervical spine injuries based on current literature and the knowledge of the Spine Section of the German Society for Orthopaedics and Trauma.

**Methods:** This recommendation summarizes the knowledge of the Spine Section of the German Society for Orthopaedics and Trauma.

**Results:** Therapeutic goals are a stable, painless cervical spine and protection against secondary neurologic damage while retaining maximum possible motion and spinal profile. The AOSpine classification for subaxial cervical injuries is recommended. The Canadian C-Spine Rule is recommended to decide on the need for imaging. Computed tomography is the favoured modality. Conventional x-ray is preserved for cases lacking a “dangerous mechanism of injury.” Magnetic resonance imaging is recommended in case of unexplained neurologic deficit, prior to closed reduction and to exclude disco-ligamentous injuries. Computed tomography angiography is recommended in high-grade facet joint injuries or in the presence of vertebra-basilar symptoms. A0-, A1- and A2-injuries are treated conservatively, but have to be monitored for progressive kyphosis. A3 injuries are operated in the majority of cases. A4- and B- and C-type injuries are treated surgically. Most injuries can be treated with anterior plate stabilization and interbody support; A4 fractures need vertebral body replacement. In certain cases, additive or

<sup>1</sup> Berufsgenossenschaftliche Unfallklinik Frankfurt, Frankfurt, Germany

<sup>2</sup> University Hospital RWTH Aachen, Aachen, Germany

<sup>3</sup> BGU Tübingen, Tübingen, Germany

<sup>4</sup> BG Klinikum Bergmannstrost Halle, Halle, Sachsen-Anhalt, Germany

<sup>5</sup> Klinikum Traunstein, Traunstein, Bayern Germany

<sup>6</sup> Gemeinschaftsklinikum Mittelrhein, Koblenz, Rheinland-Pfalz, Germany

<sup>7</sup> Universitätsklinikum Munster, Munster, Nordrhein-Westfalen, Germany

<sup>8</sup> St Josefs Hospital, Wiesbaden, Germany

<sup>9</sup> Universitätsklinikum Leipzig, Leipzig, Sachsen, Germany

<sup>10</sup> BG Unfallklinik Ludwigshafen, Ludwigshafen, Rheinland-Pfalz, Germany

<sup>11</sup> Klinikum Ingolstadt GmbH, Ingolstadt, Bayern, Germany

<sup>12</sup> Medizinische Hochschule Hannover, Hannover, Germany

<sup>13</sup> Universitätsklinikum Aachen, Aachen, Nordrhein-Westfalen, Germany

<sup>14</sup> Klinikum Sudstadt Rostock, Rostock, Germany

<sup>15</sup> Schon Klinik Hamburg-Eilbek, Hamburg, Germany

<sup>16</sup> Schön Klinik Nürnberg Fürth, Fürth, Germany

<sup>17</sup> Helios Hospital Siegburg, Germany

<sup>18</sup> BG Unfallklinik Murnau, Murnau, Bayern, Germany

<sup>19</sup> Klinikum Traunstein, Traunstein, Bayern, Germany

## Corresponding Author:

Philipp Schleicher, Berufsgenossenschaftliche Unfallklinik Frankfurt, Friedberger Landstraße 430, DE-60389, Frankfurt am Main, Germany.  
Email: philipp.schleicher@bgu-frankfurt.de



This article is distributed under the terms of the Creative Commons Attribution-NonCommercial-NoDerivs 4.0 License (<http://www.creativecommons.org/licenses/by-nc-nd/4.0/>) which permits non-commercial use, reproduction and distribution of the work as published without adaptation or alteration, without further permission provided the original work is attributed as specified on the SAGE and Open Access pages (<https://us.sagepub.com/en-us/nam/open-access-at-sage>).

pure posterior instrumentation is needed. Usually, lateral mass screws suffice. A navigation system is advised for pedicle screws from C3 to C6.

**Conclusions:** These recommendations provide a framework for the treatment of subaxial cervical spine injuries. They give advice about diagnostic measures and the therapeutic strategy.

### Keywords

lower cervical spine, subaxial cervical spine, injury, fracture, treatment recommendations, consensus, German Society for Orthopaedics and Trauma, ACDF

### Methods

The following recommendations for the treatment of injuries to the subaxial cervical spine rely on the experiences of the spinal surgeons of the spine section of the German Society for Orthopaedics and Trauma (DGOU) taking into consideration the current literature.

These recommendations refer to the diagnostics and treatment of acute traumatic injuries, for example, fractures or discoligamentous instabilities of otherwise healthy, skeletally mature patients with normal bone quality in the subaxial cervical spine, which means from the third to the seventh cervical vertebra.

In case of a patient with multiple injuries, the interdisciplinary S3-guideline “polytrauma” is valid. It contains recommendations for a comprehensive treatment strategy of all concomitant injuries, including spinal injuries.<sup>1</sup> Nevertheless, the present treatment recommendations will add useful additional information for the treatment of subaxial spinal injuries also in the polytraumatized patient.

These therapeutic recommendations are the result of a consensus process of voluntary members of the spine section of the DGOU, which have congregated and formed the working group “subaxial cervical spine injury.” The project was initiated in December 2015. The members were recruited from all over Germany and from hospitals of all levels of care.

In total, there were 4 one-day meetings of around 15 to 20 surgeons discussing and developing this article. Between these 4 meetings, the consented topics were written down and sent to each member of the spine section of the DGOU for further commentary and review.

### Basic Principles

Therapeutic goals are a permanently stable, pain-free cervical spine, the avoidance of secondary neurologic damage, and/or the improvement of already existing neurologic deficits. All therapeutic measures should consider the best possible preservation of motion and restoration of the spinal profile.

This results in the major goals of diagnostics:

- Precise morphologic detection and quantification of instability as a possible source of secondary pain syndromes, deformity, or neurologic damage
- Detection of neurologic deficits and a correlation with structural injuries detected on imaging modalities

These considerations are a prerequisite and basis for all further interventions, either conservative or operative.

Nondislocated bony lesions without any instability or neurologic damage may be treated conservatively in the majority of cases. However, they have to be followed up clinically and radiologically.

The presence of an injury-related neurocompression does imply a segmental instability, so a decompression surgery should *always* be combined with some form of stabilizing procedure.

### Classification

Because of the proven reliability and the combination of morphologic and clinical parameters, use of the AOSpine classification for subaxial cervical spine injuries is recommended (figure 1).<sup>2</sup>

According to this classification, the main injury type is classified either as a compression injury (type A), disruption of either the anterior *or* the posterior tension band (type B) or disruption of both the anterior *and* the posterior tension band with translatory instability (type C).

Further relevant parameters are the type of facet joint injury (coded by the letter F), a concomitant neurologic injury (N) as well as general comorbidities (M), which have significant impact on therapeutic decisions.

#### Type A Injuries

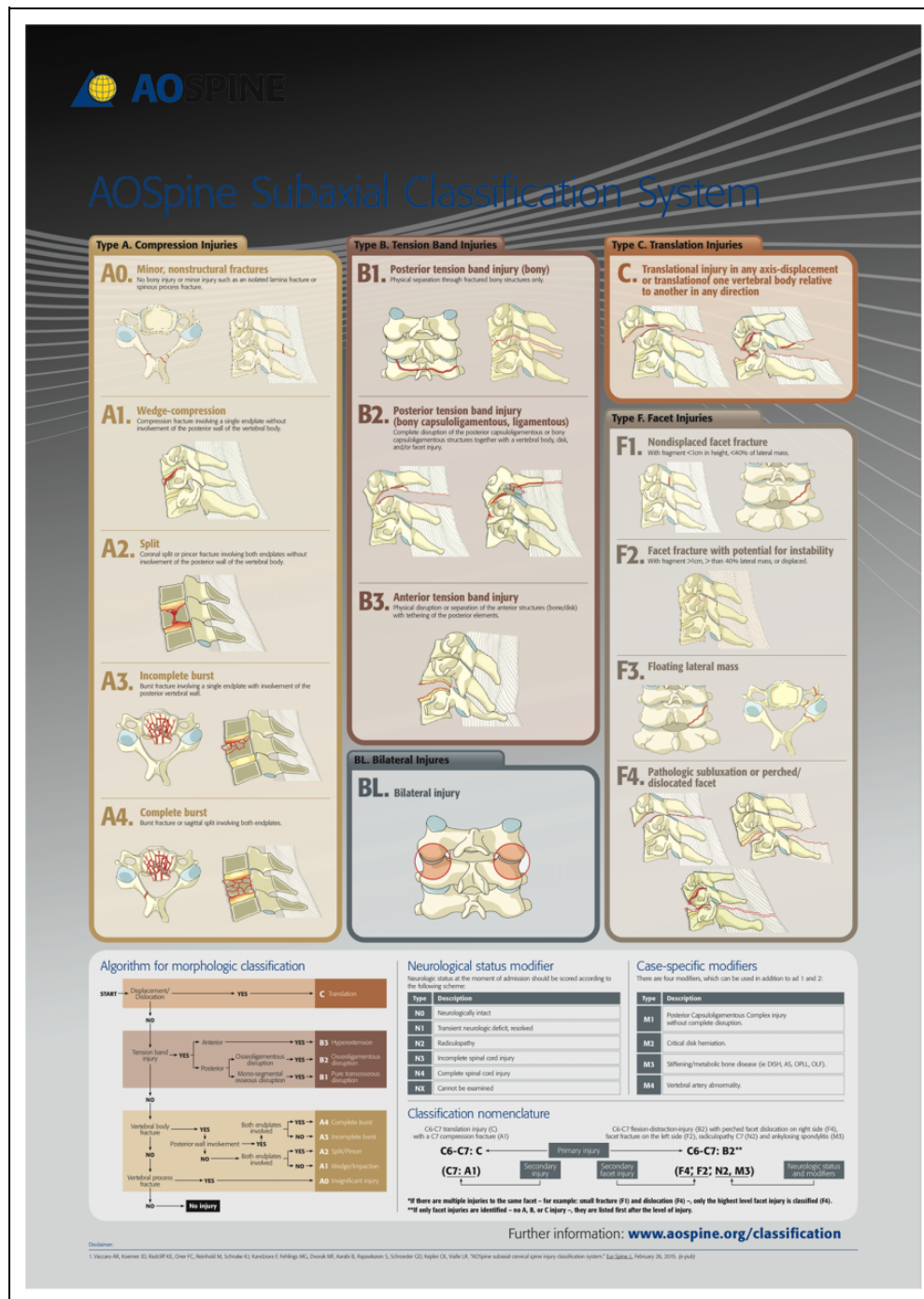
Type A injuries are subdivided into 5 subtypes:

- A0: isolated spinous or transverse process fracture without any effect on stability or a bone bruise in the magnetic resonance image (MRI) without any deformation of the vertebral body
- A1: single endplate impression without posterior wall involvement
- A2: fracture running through both endplates without posterior wall involvement (coronary split fracture)
- A3: posterior wall involvement, one endplate remains intact (superior or inferior burst fracture)
- A4: posterior wall involvement, both endplates are affected (complete burst or burst-split fracture)

#### Type B Injuries

Type B injuries are further divided into 3 subtypes:

- B1: pure osseous injury of the posterior tension band (“chance-fracture”)
- B2: osteoligamentous or ligamentous disruption of the posterior tension band
- B3: disruption of the anterior tension band (hyperextension injury)



**Figure 1.** AO spine subaxial cervical spine injury classification system (from Vaccaro et al<sup>2</sup>).

### Type C Injuries

Type c injuries are not further divided into subtypes.

### Neurologic Status

Neurologic status is grouped into 5 different classes:

N0: no neurologic impairment

N1: transient neurologic impairment, which has already resolved at the time of examination

N2: persisting radicular symptoms, either motor or sensory

N3: incomplete spinal cord injury (American Spinal Injury Association [ASIA] B-D)

N4: complete spinal cord injury (ASIA A)

### Facet Joint Injuries

Facet joint injuries are divided into 4 subgroups:

F1: nondisplaced fractures which do not affect more than 1 cm or more than 40% of the facet joint dimension

F2: displaced fractures or fractures affecting more than 1 cm or more than 40% of facet joint dimension

F3: fracture of the pedicle and the lamina of the same vertebral body, which separates the lateral mass from the rest of the vertebra (“floating lateral mass”)

F4: subluxation of more than 50% or perched luxation. These injuries are definitely a sign of severe disruption of the posterior tension band and therefore an indicator for at least a B-type or even C-type injury.

In case of a bilateral injury of the identical severity, the letters “BL” will be added after the code.

Some specific comorbidities have severe influence on the therapeutic regime and will be coded as so called “modifiers” with the letter “M”:

M1: this is a posterior capsuloligamentous injury without complete disruption, mainly seen on the MRI. It usually shows focal midline tenderness.

M2: this is a critical disc herniation behind the posterior wall of the affected vertebral bodies.

M3: stiffening/metabolic disease (eg, ankylosing spondylitis or diffuse idiopathic skeletal hyperostosis [DISH])

M4: injury of the vertebral artery

Further information to the utilized classification system may be obtained from the original publications.<sup>2</sup>

## Diagnostics

### Patient History and Physical Examination

At the beginning of the diagnostic process, patient history, including trauma mechanism and physical examination, has to be obtained.

It is recommended to use a structured protocol, which is validated and should be based on anamnestic and clinical data. Because of its proven high sensitivity, the application of the Canadian C-Spine Rule (CCR) is recommended.<sup>3-5</sup>

According to the results of this algorithm, a significant injury can be excluded with high probability—or the decision for further imaging studies can be made.

When taking history, the mechanism and exact time of injury should be obtained. It is crucial to differentiate acute neck pain, radicular pain, and any signs of neurologic impairment (paresthesia, hypoesthesia).

There are several trauma mechanisms, which bear a high probability for significant injury and are therefore assigned as “dangerous mechanisms”:

- Fall >1 m
- Axial loading on the cervical spine
- Motor vehicle accidents with
  - >100 km/h speed
  - roll over

- passenger ejection
- bicycle or quad accident
- collision with bus or truck

After having excluded any of these criteria, a physical examination of the conscious and cooperative patient should be performed. This should definitely include testing for midline tenderness and ability to rotate the head 45° to the left and to the right. The movement should be executed actively by the patients.

A neurologic examination for motor and sensory disturbances is mandatory. Any motor impairment should be quantified according to ASIA/ISCI. It is recommended to use the ASIA/ISCoS scoresheet for documentation of the neurologic status, which is freely available at [http://www.asia-spinalinjury.org/elearning/ASIA\\_ISCOS\\_high.pdf](http://www.asia-spinalinjury.org/elearning/ASIA_ISCOS_high.pdf).

The first examination should be performed before induction of any sedation. Any pathologic finding during this examination process will immediately lead to a stop in the examination and indicates further imaging.

### Imaging

**Computed Tomography.** A multislice spiral CT is the imaging modality of first choice in any

- unconscious patient with suspected cervical spine trauma
- dangerous trauma mechanism according to Canadian C-Spine Rule
- neurologic impairment.

The authors recommend 1 mm or less slice thickness and 2-dimensional (2D) reconstructions in the 3 standard planes (sagittal, transverse, coronary) as minimum requirements, a 3D surface reconstruction might be helpful in specific situation (eg, in a facet joint fracture).

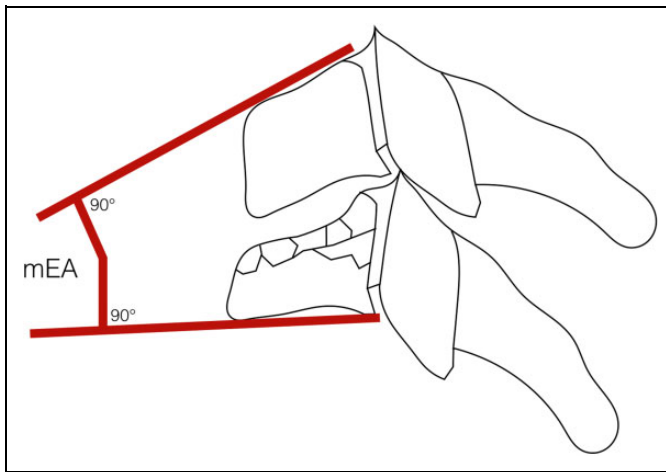
Conventional x-ray is possible in selected cases to reduce radiation dosage, especially when imaging is indicated according to Canadian C-Spine rule, but a dangerous trauma mechanism or a neurologic impairment can be excluded.

In all doubtful cases, especially when the cervicothoracic junction is not displayed in an appropriate manner, CT or MRI should be used for further evaluation.

It is important to recognize that a negative finding on conventional x-ray cannot exclude any significant injury with an appropriate level of certainty.<sup>6,7</sup>

**Angiography.** In lower grade facet joint fracture (F1, F2) or when a fracture line radiates into the facet joint, a CT angiogram should be considered. In higher grade facet joint injury (F3, F4), any B-type or C-type injury and in the presence of vertebrobasilar symptoms, a CT- or MR-angiogram is recommended.<sup>8</sup>

**Magnetic Resonance Imaging.** In any case of a neurologic impairment, which cannot fully be explained by the results of the CT scan, an MRI is to be obtained as soon as possible.



**Figure 2.** The monosegmental endplate angle (mEA) is the angle between the distal (superior) endplate of the vertebra next to the fractured endplate and the intact endplate of the fractured vertebral body in AOSpine A3 fractures.

Any facet joint injuries (F1-F3) should lead to an MRI for recognition of a discoligamentous injury, if there is still doubt about the necessity or extent of any surgical stabilization. Any other suspicion for a disco-ligamentous injury also indicates an MRI.

Persistent neck pain without any good explanation in the other imaging modalities shall lead to an MRI during follow-up. An MRI is recommended in case of planning an isolated posterior approach in a perched facet joint luxation to recognize any dislocated disc material behind the vertebral body, which might cause cord compression after closed or open posterior reduction.

**Dynamic X-Ray.** In the neurologically intact patient, who shows suspicious findings for segmental instability in CT or MRI, a dynamic fluoroscopy in flexion and extension might add diagnostic value. This examination should be performed by an experienced physician only.

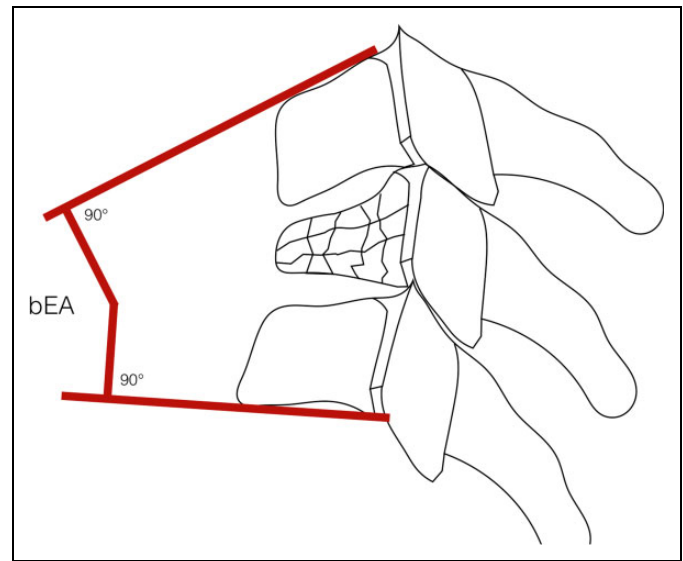
A static flexion/extension radiograph without passive guidance by a physician is definitely not recommended due to proven lack of therapeutic consequences.<sup>9</sup>

**Radiographic Parameters.** We recommend the following measurements to be obtained in the imaging studies.

If there is a monosegmental pathology (ie, A3-fracture, B2-fracture with A3 component, facet joint injury), the monosegmental endplate angle (mEA, Figure 2) is measured between the upper endplate of the superior vertebra and the inferior endplate of the inferior vertebra of the affected segment.

In case of a bisegmental pathology (ie, A4-fracture, F3-floating lateral mass), the bisegmental endplate angle (bEA, Figure 3) is to be obtained, which is measured between the upper endplate of the vertebra the upper affected segment and the inferior endplate of the inferior affected segment.

$\Delta$ EA (Delta-EA) is the difference between the measured angle and the normal value in this specific segment (see Table 1). Translation is to be measured as the distance between the



**Figure 3.** The bisegmental endplate angle (bEA) is the angle between the superior endplate of the vertebra superior to the fractured vertebral body and the inferior endplate of the vertebra inferior to the fractured vertebra in AOSpine A4 fractures.

**Table 1.** Normal Values for the Segmental Endplate Angles.<sup>a</sup>

Segment	Angle, deg, Mean $\pm$ SD
C2-C3	$-1.9 \pm 5.2$
C3-C4	$-1.5 \pm 5.0$
C4-C5	$-0.6 \pm 4.4$
C5-C6	$-1.1 \pm 5.1$
C6-C7	$-4.5 \pm 4.3$
C2-C7	$-9.6$

<sup>a</sup>A negative values means lordosis, and a positive value means kyphosis. Data from Reinhold et al.<sup>12</sup>

posterior wall tangent of the upper and lower vertebral body at the level of the upper endplate of the lower vertebral body.

### Instability Criteria

According to the imaging findings, we define the following criteria as signs for instability (modified according to Vaccaro et al,<sup>2</sup> White and Panjabi,<sup>10</sup> and Spector et al<sup>11</sup>)

- subluxation of a facet joint (less than 50% overlap)
- fracture of a facet joint (more than 10 mm or 40% of the facet joint surface)
- sagittal translation (more than 3.5 mm)
- more than 15°  $\Delta$ -EA

## Therapy

### Therapeutic Strategies

Possible therapeutic options include early functional conservative management with external immobilization using cervical

collars with different degrees of rigidity, Halo vest immobilization as well as anterior and/or posterior stabilization with decompression if indicated.

In general, the therapeutic strategy, which should be closely reevaluated over the course of treatment, depends on 2 main criteria: first on the injury morphology and second on individual patient criteria as age, general health, bone quality, and biomechanically important bony changes (DISH, ankylosing spondylitis).

The assessment and classification of the injury according to the AOSpine classification for subaxial injuries facilitates therapeutic decision making. Furthermore, the risk of progressive kyphotic angulation and consequent deterioration of the sagittal profile should be taken into account.

The urgency for surgical management mainly depends on existent or imminent neurological deficits and on the degree of instability.

### **A0-Fractures**

A0-Fractures are stable and are treated with early functional conservative therapy with adequate pain medication. A soft cervical collar may be used for pain relief for a short period (maximum 6 weeks).

### **A1-Fractures**

A1-fractures are stable and are in most cases managed with early functional conservative therapy, as described for A0-fractures, with excellent results. In rare cases, a significant kyphotic deformity is present or may develop in the course; thus the monosegmental kyphotic angulation should be measured initially, during the course and after 6 weeks. An increase in kyphotic angulation  $>15^\circ$  ( $\Delta$ -mEA) may be an indication for anterior monosegmental (rarely bisegmental) fusion in view of preservation of the sagittal cervical profile.

### **A2-Fractures**

A2-fractures are stable and are usually managed with early functional conservative therapy similarly to A1-fractures. Also, in A2-fractures, an increase in kyphotic angulation  $>15^\circ$  ( $\Delta$ -bEA) may be an indication for anterior fusion in view of preservation of the sagittal cervical profile; however, in contrast to A1-fractures always a bisegmental fusion should be performed.

### **A3-Fractures**

A3-fractures include the risk of posterior wall dislocation and of concomitant neurological impairment. Furthermore, the risk of secondary kyphotic angulation is considerably higher as compared with A1- and A2-fractures. Therefore, anterior fusion is recommended either in a mono- or bisegmental manner, depending on the degree of vertebral destruction.

Oligosymptomatic patients with a  $\Delta$ -mEA of less than  $15^\circ$  and no relevant narrowing of the spinal canal with preservation of the liquor space may be treated conservatively with a

rigid cervical collar for 6 weeks. In these cases, the bisegmental kyphotic angulation should be measured initially, during the course of treatment and after 6 weeks closely.

### **A4-Fractures**

A4-fractures show a high degree of vertebral destruction with involvement of both endplates and both adjacent discs and should be recognized as unstable injuries. The risk of posterior wall dislocation and of concomitant neurological impairment as well as the risk of secondary kyphotic angulation is higher as compared with A3-fractures. Therefore, bisegmental anterior fusion is recommended.

### **B1-Injuries**

B1-injuries are unstable and posterior bisegmental instrumentation in terms of a tension-band fixation is recommended. Fusion may not be performed in order to allow remobilization of the 2 motion segments after implant removal following bony healing.

Despite their instability, these injuries exhibit a tendency of good bony healing and may be suitable for conservative treatment in a hyperextended cervical orthosis in individual cases. This, however, requires immediate radiological control following reduction in the hyperextended cervical orthosis and short-term follow-up in the course.

### **B2-Injuries**

B2-injuries are unstable and surgical stabilization is recommended. The surgical approach (anterior, posterior, or combined) as well as the decision for fusion length (mono- or bisegmental) mainly depends on the A-component (degree of vertebral body destruction) of this injury.

### **B3-Injuries**

B3-injuries are unstable and anterior monosegmental fusion is recommended. In case of ankylosing spondylitis (M3) different principles should be applied (see below).

### **C-Injuries**

C-injuries are highly unstable and urgent surgical stabilization is recommended. Because of the high variability of C-injuries an individual therapeutic strategy is indicated. However, the surgical approach (anterior, posterior combined) as well as the decision for fusion length (mono-, bi-, or multisegmental) is highly influenced by the A-component (degree of vertebral body destruction) of this injury.

### **Facet Joint Injuries**

**F1-Injuries (Stable Facet Fractures).** F1-injuries are stable and are treated with early functional conservative therapy with adequate pain medication. A cervical collar may be used for pain relief for a short period (maximum 6 weeks). Radiological

follow-up in the course and after 6 weeks is recommended to recognize secondary dislocation.

**F2-Injuries (Unstable Facet Fractures).** F2-injuries are usually components of unstable B- or C-injuries, which dictate the surgical strategy. Possible nerve root compression by the facet fragment may therefore require an additional posterior approach in case of an anterior stabilization.

**F3-Injuries (Floating Lateral Mass).** F3-injuries are components of unstable B- or C-injuries, which dictate the surgical strategy. Possible nerve root compression by the facet fragment may therefore require an additional posterior approach in case of anterior stabilization. Because the underlying instability usually involves the cranial and caudal adjacent segments, these should be included in the stabilization.

**F4-Injuries (Subluxation or Perched/Dislocated Facet).** F4-injuries are components of unstable B- or C-injuries, which dictate the surgical strategy. Possible nerve root compression by the facet fragment may therefore require an additional posterior approach in case of an anterior stabilization.

Unilateral or bilateral locked facets require a differentiated concept in order to ensure a safe reduction without neurological compromise.

In general, closed reduction should be performed under fluoroscopy by an experienced spine surgeon under operating room (OR) standby or directly in the OR.<sup>12</sup> To ease closed reduction patient relaxation is recommended. Because there is an inverse correlation between time since luxation and reduction success, closed reduction should be performed as early as safely possible.

In neurologically intact patients, it is recommended to perform closed reduction in the anesthetized patient in the OR directly prior to surgery. In case a closed reduction is not possible, immediate anterior decompression is performed, followed by an open reduction attempt with a distractor (eg, Caspar-distractor). Usually, reduction should be achieved with this algorithm in more than 95% of locked facets.<sup>13,14</sup> In the rare case that an anterior open reduction may not be achieved, the reduction has to be performed by an open posterior approach following the mandatory complete anterior decompression.

In case the surgeon prefers primary open posterior reduction, a preoperative MRI is mandatory to exclude herniated disc material, which may constrain the spinal canal following reduction without anterior decompression (see section "Diagnostics").

Patients with neurological compromise should undergo reduction as soon as possible; however, benefits and risks of immediate reduction should be thoroughly assessed.

## Therapeutic Principles

### Conservative Therapy

Until now the level of evidence concerning conservative treatment of bony or ligamentous subaxial cervical injuries has been

low. Limitation of cervical range of motion with cervical collars of different degrees of rigidity is usually one component of conservative therapy. Bony injuries with minor instability (A1-, A2- and F1-injuries; in some hands also A3-injuries) should be stabilized with a semirigid collar (eg, Philadelphia collar).

Of all conservative therapeutic options, the Halo vest offers the highest stability; however, Halo ring application is invasive and associated with a noteworthy complication rate. Therefore, the Halo vest should be used only in rare cases with high instability, in which either a definite stabilization may not be performed in a timely manner or inoperability is given.

In general, immobilization should be maintained for at least 6 weeks, but no longer than 12 weeks. Persistent symptoms should indicate reevaluation of the conservative treatment strategy. Adjunct pain medication should be administered according to the World Health Organization (WHO) pain ladder.

Conservative therapy must always involve regular clinical and radiological follow-ups for 8 to 12 weeks following trauma. Each clinical deterioration must imply a radiological assessment in order not to miss a secondary dislocation.

Stabilizing but nonmobilizing physical therapy of the cervical spine should be started as early as possible. Once healing has been radiologically confirmed, a mobilizing physical therapy should be started. Additional physical applications (eg, hot/cold massage) are optional.

### Surgical Therapy

**Positioning.** Since the indication for surgery is usually based on cervical instability, stable positioning allowing all possibilities of reduction should be performed (head frame, Mayfield-clamp, Halo ring). Furthermore, positioning should not interfere with intraoperative fluoroscopy.

**Approach.** The approach is mainly determined by the injury morphology as described above. Nonetheless, the anterolateral Smith-Robinson approach is suitable for most subaxial cervical injuries. Whether a left- or right-sided anterolateral approach is beneficial especially in terms of recurrent laryngeal nerve palsy is not final answered by literature; however, cuff pressure should be adjusted after all retractors have been placed.<sup>15,16</sup>

In case a posterior approach is required, the posterior midline approach is the posterior standard approach. Modified posterior approaches may become necessary for percutaneous instrumentation or minimal invasive decompression.

**Instrumented Fusion.** The main goals of surgically treated subaxial cervical injuries are reduction, retention, and fusion of the injured segments. To maintain the reduction until bony fusion is achieved, an instrumentation of the injured segments is mandatory.

In case of anterior stabilization, interbody support (mono- or multisegmental) is necessary and is achieved by the use of cages (titanium, PEEK [polyetheretherketone]), iliac cortical



crest, or allogenic bone transplants. An angular-stable anterior plate is mandatory for adequate stability.

In case of posterior stabilization, divergently placed lateral mass screws (technique as described by Magerl or Roy-Camille) are advocated and offer a lower risk of vertebral artery injury and sufficient biomechanical strength.<sup>17</sup>

In selected cases, pedicle screws may become advantageous due to the higher biomechanical stability.<sup>18-20</sup> In these cases, navigation or intraoperative 3D imaging is recommended for safe placement of pedicle screws between C3 and C6.<sup>21-23</sup>

**Decompression.** Decompression is necessary in case of neurological impairment with corresponding radiological pathology. This is true for intraspinal (eg, posterior wall fragment/herniated disc/hematoma/spinal cord edema) as well as for neuroforaminal (eg, facet joint fragment) pathologies. Ideally, the decompression is performed at the site of the pathology (direct decompression); however, in some cases the surgical approach and stabilization tactic may favour an indirect decompression.

Prophylactic decompression may be an option for injuries in which surgical stabilization is necessary and neurological deterioration is feared.

**Cortisone Application.** High-dose cortisone application (NASCIS II) in paraplegic patients is no longer recommended independently of the treatment strategy. There is good evidence that adverse events as respiratory complications or gastrointestinal bleeding outweigh the potential benefits. Clear contraindications even exist for multiple injured patients or geriatric patients with multiple comorbidities.<sup>24-26</sup>

**Postoperative Care.** Each surgical stabilization should aim at functional stability. Nonetheless, a cervical collar may be helpful to reduce postsurgical pain and to limit range of motion.

Adjunct pain medication should be administered according to the WHO pain ladder.

Surgical therapy should be accompanied by regular clinical and radiological follow-ups. Each clinical deterioration must imply a radiological assessment. Injuries with a postsurgical stable situation should receive physical therapy in the postsurgical course.

A scheduled implant removal is only indicated in individual cases as temporary inclusion of an uninjured segment or implant-associated pain. Verification of bony healing is mandatory in all cases planned for implant removal.

**Modified Strategy in Ankylosing Diseases (Modifier M3).** Fractures in patients with ankylosing disease (eg, ankylosing spondylitis, DISH) show a different biomechanical behaviour due to the long lever arm. These fractures are usually highly unstable with tendency of further dislocation if not stabilized. The postsurgical course may be further complicated by implant loosening and nonunion, both mainly attributable to the frequently coexisting osteoporosis in these patients.

Multilevel spinal injuries are common in patients with ankylosing spondylitis and should find consideration in the diagnostic strategy (eg, CT scan of the entire spine).

Neurological impairment and intraspinal hematoma, which may also appear later in the course, are often seen in these patients. Therefore, the indication for an MRI should be considered generously.

Surgical stabilization of fractures in patients with ankylosing disease is the therapy of choice. Although the preexisting spinal fusion results in a long lever arm with increased stress on the instrumentation, it also allows for long stabilizing constructs without impairment of the range of motion. Therefore, a posterior multilevel stabilization is recommended in these patients.

Reduction of the preinjury sagittal profile is not mandatory; instead correction of a preexisting kyphotic deformity is often possible.

## Conclusion

These recommendations provide a framework for the treatment of subaxial cervical spine injuries. They represent the current opinion of leading spine surgeons of the Spine Section of the German Society for Orthopaedics and Trauma, based on many years' experience and scientific knowledge, adapted to the German health care system. They give advice about the indication of diagnostic measures on clinical and anamnestic factors.

## Authors' Note

This article has previously been published in German language in the journal *Zeitschrift für Orthopädie und Unfallchirurgie*.

## Acknowledgments

We would like to thank the native English-speaking Mrs Jennifer J. Koepp for the critical review of the manuscript regarding the English language.


## Declaration of Conflicting Interests

The author(s) declared no potential conflicts of interest with respect to the research, authorship, and/or publication of this article.

## Funding

The author(s) received no financial support for the research, authorship, and/or publication of this article.

## ORCID iD

Maximilian Reinhold  <http://orcid.org/0000-0003-0336-6043>

## References

1. Deutsche Gesellschaft für Unfallchirurgie. S3-Leitlinie. Polytrauma/Schwerverletztenbehandlung. <http://www.awmf.org/leitlinien/detail/II/012-019.html>. Accessed October 10, 2016.
2. Vaccaro AR, Koerner JD, Radcliff KE, et al. AOSpine subaxial cervical spine injury classification system. *Eur Spine J*. 2016;25:2173-2184.
3. Stiell IG, Clement CM, McKnight RD, et al. The Canadian C-spine rule versus the NEXUS low-risk criteria in patients with trauma. *N Engl J Med*. 2003;349:2510-2518.



4. Stiell IG, Wells GA, Vandemheen KL, et al. The Canadian C-spine rule for radiography in alert and stable trauma patients. *JAMA*. 2001;286:1841-1848.
5. Hoffman JR, Mower WR, Wolfson AB, Todd KH, Zucker MI. Validity of a set of clinical criteria to rule out injury to the cervical spine in patients with blunt trauma. National Emergency X-Radiography Utilization Study Group. *N Engl J Med*. 2000;343:94-99.
6. Bailitz J, Starr F, Beecroft M, et al. CT should replace three-view radiographs as the initial screening test in patients at high, moderate, and low risk for blunt cervical spine injury: a prospective comparison. *J Trauma*. 2009;66:1605-1609.
7. Holmes JF, Akkinepalli R. Computed tomography versus plain radiography to screen for cervical spine injury: a meta-analysis. *J Trauma*. 2005;58:902-905.
8. Harrigan MR, Hadley MN, Dhall SS, et al. Management of vertebral artery injuries following non-penetrating cervical trauma. *Neurosurgery*. 2013;72(suppl 2):234-243.
9. McCracken B, Klineberg E, Pickard B, Wisner DH. Flexion and extension radiographic evaluation for the clearance of potential cervical spine injuries in trauma patients. *Eur Spine J*. 2013;22:1467-1473.
10. White AA, Panjabi MM. *Clinical Biomechanics of the Spine*. 2nd ed. Baltimore, MD: Lippincott Williams & Wilkins; 1990:1.
11. Spector LR, Kim DH, Affonso J, Albert TJ, Hilibrand AS, Vaccaro AR. Use of computed tomography to predict failure of non-operative treatment of unilateral facet fractures of the cervical spine. *Spine (Phila Pa 1976)*. 2006;31:2827-2835.
12. Reinhold DM, Knop C, Lange U, Rosenberger R, Schmid R, Blauth M. Reduction of traumatic dislocations and facet fracture-dislocations in the lower cervical spine [in German]. *Unfallchirurg*. 2006;109:1064-1072.
13. Aebi M. Surgical treatment of upper, middle and lower cervical injuries and non-unions by anterior procedures. *Eur Spine J*. 2010;19(suppl 1):S33-S39.
14. Reindl R, Ouellet J, Harvey EJ, Berry G, Arlet V. Anterior reduction for cervical spine dislocation. *Spine (Phila Pa 1976)*. 2006;31:648-652.
15. Jung A, Schramm J. How to reduce recurrent laryngeal nerve palsy in anterior cervical spine surgery: a prospective observational study. *Neurosurgery*. 2010;67:10-15.
16. Audu P, Artz G, Scheid S, et al. Recurrent laryngeal nerve palsy after anterior cervical spine surgery: the impact of endotracheal tube cuff deflation, reinflation, and pressure adjustment. *Anesthesiology*. 2006;105:898-901.
17. Yoshihara H, Passias PG, Errico TJ. Screw-related complications in the subaxial cervical spine with the use of lateral mass versus cervical pedicle screws: a systematic review. *J Neurosurg Spine*. 2013;19:614-623.
18. Ito Z, Higashino K, Kato S, et al. Pedicle screws can be 4 times stronger than lateral mass screws for insertion in the midcervical spine: a biomechanical study on strength of fixation. *J Spinal Disord Tech*. 2014;27:80-85.
19. Kothe R, Rütther W, Schneider E, Linke B. Biomechanical analysis of transpedicular screw fixation in the subaxial cervical spine. *Spine (Phila Pa 1976)*. 2004;29:1869-1875.
20. Johnston TL, Karaikovic EE, Lautenschlager EP, Marcu D. Cervical pedicle screws vs lateral mass screws: uniplanar fatigue analysis and residual pullout strengths. *Spine J*. 2006;6:667-672.
21. Hojo Y, Ito M, Suda K, Oda I, Yoshimoto H, Abumi K. A multicenter study on accuracy and complications of freehand placement of cervical pedicle screws under lateral fluoroscopy in different pathological conditions: CT-based evaluation of more than 1,000 screws. *Eur Spine J*. 2014;23:2166-2174.
22. Cong Y, Bao N, Zhao J, Mao G. Comparing accuracy of cervical pedicle screw placement between a guidance system and manual manipulation: a cadaver study. *Med Sci Monit*. 2015;21:2672-2677.
23. Shimokawa N, Takami T. Surgical safety of cervical pedicle screw placement with computer navigation system. *Neurosurg Rev*. 2017;40:251-258.
24. Bracken MB. Steroids for acute spinal cord injury. *Cochrane Database Syst Rev*. 2012;1:CD001046.
25. Fehlings MG, Wilson JR, Cho N. Methylprednisolone for the treatment of acute spinal cord injury: counterpoint. *Neurosurgery*. 2014;61(suppl 1):36-42.
26. Hurlbert RJ. Methylprednisolone for the treatment of acute spinal cord injury: point. *Neurosurgery*. 2014;61(suppl 1):32-35.