Clinical and Translational Radiation Oncology 49 (2024) 100853

Contents lists available at ScienceDirect

Clinical and Translational Radiation Oncology

journal homepage: www.sciencedirect.com/journal/clinical-and-translational-radiation-oncology

Original Research Article

# Prognostic implications of HIF-1α expression in anal squamous cell carcinoma treated with intensity-modulated radiotherapy (IMRT)

Ahmed Allam Mohamed [a,c,*], Michael J. Eble [a,c], Edgar Dahl [b,c], Danny Jonigk [b,c,d], Svetlana Warkentin [b,c]

[a] Department of Radiation Oncology, RWTH Aachen University, Aachen, Germany
[b] Institute of Pathology, RWTH Aachen University, Aachen, Germany
[c] Center for Integrated Oncology Aachen, Bonn, Cologne and Duesseldorf (CIO ABCD), Aachen, Germany
[d] Biomedical Research in Endstage and Obstructive Lung Disease Hannover (BREATH), German Center of Lung Research (DZL), Hanover, Germany

ARTICLE INFO

*Keywords:*
Tumor hypoxia
Prognostic biomarker
IMRT
Anal cancer
HPV squamous cell carcinoma

ABSTRACT

*Background:* Hypoxia-inducible factor-1α (HIF-1α) is a crucial transcription factor activated under hypoxic conditions, known to regulate genes associated with tumor survival, progression, and response to therapy. This study aimed to evaluate the prognostic significance of HIF-1α expression in patients with anal squamous cell carcinoma (ASCC) undergoing chemoradiation therapy.

*Methods:* We conducted a retrospective analysis of 28 ASCC patients treated with intensity-modulated radiotherapy (IMRT) at our center from 2009 to 2022. HIF-1α expression was assessed via immunohistochemistry on formalin-fixed paraffin-embedded tissue specimens. Quantitative analysis of HIF-1α expression was performed, and its relationship with clinical outcomes, including disease-free survival (DFS), locoregional relapse-free survival (LRRFS), and overall survival (OS), was examined using Cox regression models. Furthermore, ASCC tissue specimens from 17 patients were analyzed for potential *PIK3CA* mutations using Sanger sequencing.

*Results:* High HIF-1α expression was significantly associated with poorer DFS ($p = 0.005$), LRRFS ($p = 0.012$), and OS ($p = 0.009$). HIF1α expression was marginally significantly higher in males compared to females ($p = 0.056$) while there was no significant difference found based on tumor stage or p16 status. However, a positive correlation was identified between BMI and HIF-1α levels (Pearson correlation $r = 0.5$, $p = 0.0084$), suggesting a link between metabolic status and tumor hypoxia. Only one patient exhibited a PIK3CA mutation, preventing a reliable assessment of its correlation with HIF-1α expression.

*Conclusion:* Our findings underscore the importance of HIF-1α as a potential biomarker for predicting survival outcomes in ASCC patients treated with chemoradiation. The association between higher BMI and increased HIF-1α expression may provide insights into the interplay between metabolic health and tumor biology in ASCC. Further studies with larger cohorts are needed to validate these findings and explore targeted therapies focusing on HIF-1α modulation.

## Introduction

Anal squamous cell carcinoma (ASCC) is a rare malignancy that affects women more than men, with upwards trends for mortality [1]. The mainstay for treatment in non-metastatic stages is radiotherapy concurrent with fluoropyrimidines and mitomycin, which has a higher chance of sphincter-sparing [2,3]. Currently, efforts are being made to customize radiation doses according to tumor stage, reducing the intensity for early stages while increasing it for advanced stages [4].

Hypoxia is common in solid tumors due to the imbalance between the high oxygen demand of cancer cells and the insufficient oxygen supply provided by aberrant peritumoral vascularization and blood flow [5]. This hypoxic microenvironment promotes the development of a more aggressive carcinoma phenotype characterized by high metastatic rates, resistance to therapeutic agents, and increased tumor recurrence [6]. As a result, therapeutic efficacy is reduced, leading to poorer patient outcomes [7]. Hypoxia-inducible factor-1 (HIF-1) is a pivotal transcription factor that exists as a heterodimer with two subunits, "α" and

* Corresponding author at: Universitätsklinik RWTH Aachen, Pauwelstraße 30, 52074 Aachen, Germany.
*E-mail address:* amohamed@ukaachen.de (A.A. Mohamed).

https://doi.org/10.1016/j.ctro.2024.100853
Received 9 June 2024; Received in revised form 28 August 2024; Accepted 1 September 2024
Available online 3 September 2024
2405-6308/© 2024 The Author(s). Published by Elsevier B.V. on behalf of European Society for Radiotherapy and Oncology. This is an open access article under the CC BY-NC-ND license (http://creativecommons.org/licenses/by-nc-nd/4.0/).

"β" [8]. Being activated through hypoxia and various non-hypoxic pathways, including growth factors signaling and oncogenic pathways, HIF-1α is crucial for activation for angiogenesis, proliferation, and metastases of tumors [9].

Despite numerous attempts to identify prognostic biomarkers for ASCC [10,11], the role of hypoxia has seldom been explored, and HIF-1α has not previously been evaluated in this context [12].

In this study, we aim to explore the prognostic significance of HIF-1α in ASCC patients undergoing IMRT, as well as the factors that may influence its expression.

## Material and methods

After approval by the local ethics committee of the Faculty of Medicine, RWTH Aachen University (EK 22-312), we conducted this retrospective analysis of clinical data from patients diagnosed with ASCC who underwent intensity-modulated radiotherapy (IMRT) at our center from 2009 to December 2022, as detailed in previous reports [13,14]. This analysis included individuals treated with the intent to cure and for whom archived, formalin-fixed paraffin-embedded (FFPE) tissue specimens from primary tumors were available for analysis. Exclusion criteria were patients presenting with metastatic disease at initial diagnosis and those for whom only FFPE tissue from metastatic sites was available.

First, the slides stained with hematoxylin and eosin were analyzed for the presence, quantity, and quality of the tumor cells. After that, immunohistochemistry (IHC) was performed on 4 μm thick tissue sections. After deparaffinization and rehydration, the antigen was retrieved using a citrate buffer (pH 6.0). Sections were then incubated with a commercial monoclonal rabbit anti-HIF-1α antibody (EP118, HIF-1 alpha antibody, Bio SB, 108 Santa Barbara, CA 93111, USA) at a dilution of 1:250 for 30 min at room temperature. Following primary antibody incubation, tissue sections were treated with a biotinylated secondary antibody, followed by exposure to an avidin–biotin complex with horseradish peroxidase. Colorimetric detection was performed using 3,3′-diaminobenzidine (DAB) as a chromogen. Finally, sections were counterstained with hematoxylin, dehydrated, and mounted. This staining was performed by hand. Other IHC analysis of specimens without known p16-status was performed similarly with anti-$p16^{INK4a}$ primary antibody (ZYTOMED Systems, Berlin, Germany) in 1:800 dilution and pretreatment at pH 9.0, automatically in Dako Omnis platform (Agilent, Waldbronn, Germany).

Quantification of HIF-1α expression was achieved by capturing digital images of the stained sections with a whole slide scanner Hamamatsu NanoZoomer 2.0HT (Hamamatsu, Geldern, Germany). A semi-quantitative scoring method was utilized based on the prevalence and intensity of HIF-1α expression among the cells. Slides were reviewed independently by a gastrointestinal pathologist (SW), blinded to the clinical outcomes, and the percentage of tumor cells exhibiting nuclear or cytoplasmic HIF-1α staining was estimated. Next, the median intensity of expression was determined using ImageJ software from 3 representative areas from the sample using squamous epithelial tissue from the tonsils as a positive control. An average value of HIF-1α expression was calculated, representing the percentage of cells expressing HIF-1α and the intensity of expression. Subsequently, a Receiver Operating Characteristic (ROC) analysis was conducted utilizing disease-free survival as a benchmark to dichotomize HIF-1α expression into 'low' and 'high' categories Fig. 2.

ASCC samples were subsequently analyzed for activating mutations in the *PIK3CA* gene. Tumor cell fraction was at least >20 % in all cases. DNA extraction from FFPE samples was done as described previously [15] Amplification of exon 4, exon 7, exon 9, and exon 20 of the *PIK3CA* gene by PCR was achieved using the primers shown in Table 1-Supplementary. PCR conditions were as follows: 40 cycles at 95 °C for 40 s, 60 °C for 40 s, and 72 °C for 40 s, followed by a final extension at 72 °C for 5 min. For exon 9 amplification, annealing was done at 55 °C. Sanger sequencing of PCR products was performed as described previously [15].

The patient data analyzed included demographic and clinical characteristics such as age, sex, UICC 8th edition staging, and Body Mass Index (BMI). The locoregional relapse-free survival (LRRFS) was defined as the interval from completion of treatment to the first instance of disease progression or relapse within the pelvic region. Similarly, disease-free survival (DFS) was tracked as the duration from therapy conclusion to the onset of any recurrence, local or distant. Moreover, overall survival (OS) denoted the period from initial diagnosis to death by any cause.

### *Statistical analysis*

The paired *t*-test was used to compare parametric data, whereas the Mann–Whitney *U* test was used to analyze non-parametric data. Kaplan-Meier survival curves were generated, and differences in survival distributions were assessed using the log-rank test. Cox regression analysis identified independent predictors of LRRFS, DFS, and OS. All statistical tests were two-sided, and a p-value of less than 0.05 was considered statistically significant.

Statistical analyses and graphical representations were performed using R software, version 4.3.1.

## Results

We identified FFPE samples from 32 ASCC patients treated during the abovementioned period. However, we excluded three patients as their disease was metastatic at treatment initiation and another patient as the available specimen was obtained from a metastatic site (liver) later in the disease trajectory. Consequently, 28 patients met the inclusion criteria for our analysis. Table 1 provides an overview of patient and disease characteristics. The median age was 61, and the median expression of HIF-1α was 62.5 % (range 0–100 %).

The median applied radiation dose was 56 Gy; out of the cohort, 27 patients underwent combined chemoradiation therapy (CRT), whereas one elder patient was treated with only radiotherapy. Of those receiving chemotherapy, 26 were given a regimen of fluoropyrimidine and mitomycin, while a single patient received fluoropyrimidine in combination with cisplatin.

The median follow-up time was 62.5 months, the median OS was 89 months, and the median DFS and median LRRFS were reached during

**Table 1**
Baseline characteristics –, T: primary tumor stage, N: nodal stage, *UICC-TNM 8th classification, Gy: Gray.

| Characteristics | |
|---|---|
| Sex | |
| Female | 17 (60.7%) |
| Male | 11 (39.3%) |
| median Age (range) | 61 (35-83) |
| T-stage* | |
| 1 | 3 |
| 2 | 14 |
| 3 | 4 |
| 4 | 7 |
| N-stage* | |
| 0 | 15 |
| 1 | 13 |
| disease Stage* | |
| Early (T1-2, N0) | 11 |
| Advanced (T3-4 or N1) | 17 |
| P-16 status | |
| positive | 22 |
| negative | 6 |
| median radiation dose (range) | 56 (46–46) Gy |
| concurrent chemotherapy | |
| Yes | 27 |
| No | 1 |

the analysis.

The median HIF-1α expression was marginally significantly lower in females compared to males (p-value = 0.056), but no association was observed between the level of HIF-1α expression and tumor stage (p-value = 0.81) or p16 status (p-value = 0.15) (Fig. 2a–c). Further, a positive correlation was identified between BMI and HIF-1α expression (Pearson correlation, r = 0.5, p-value = 0.0084) (Fig. 2d), but there was no correlation between Age and HIF-1α expression (r = −0.05, p = 0.79).

Out of the 28 tissue samples, only 17 were evaluable for mutations in the *PIK3CA* gene using PCR. Of these evaluable samples, only one (p16 negative and 83 % HIF-1α expression) exhibited a mutation in exon 9 of the *PIK3CA* gene, affecting codon 545 (GAG > AAG). This well-known activating mutation leads to the amino acid substitution p.(Glu545Lys) in the helical domain of the catalytic subunit of PI3K.

### *Univariate analysis*

ROC analysis was utilized to stratify HIF-1α expression into low and high categories based on DFS as the reference variable, identifying the optimal cutoff point. A threshold of 66.5 % emerged as the most effective, achieving an area under the curve (AUC) of 0.68, with corresponding sensitivity and specificity values of 0.8 and 0.72, respectively, to detect the disease recurrence (Fig. 3a).

Employing the cutoff point, 15 patients expressed HIF-1α below 66.5 % with two disease recurrence events (low HIF-1α expression), and 13 patients with HIF-1α expression ≥66.5 % experienced eight disease recurrence events (high HIF-1α expression) (Fig. 3b). High HIF-1α expression was correlated with markedly poorer DFS, with a median DFS of 30.3 months, while not reached in those with low HIF-1α expression (p-value = 0.005) (Fig. 3c). Additionally, there was a significant reduction in LRRFS for the same group (median LRRFS of 30.3 months, not reached for low HIF-1α expression, p-value = 0.012, Fig. 3d). Furthermore, the median OS was 34.6 months for this group, whereas it was not reached in those with lower HIF-1α levels (p = 0.009, Fig. 3e).

Further univariate analysis, which incorporated the status of p16, revealed that p16-positive tumors exhibited significant improvements in DFS, LRRFS, and OS compared to p16-negative tumors, with p-values of 0.033, 0.016, and 0.0038, respectively (Supplementary Fig. 1a–c). Conversely, stratifying patients into early-stage (T1/2, N0) versus advanced-stage (T3/4 and/or N1) categories did not demonstrate any statistically meaningful differences in DFS, LRRFS, and OS, with p-values of 0.77, 0.63, and 0.5, respectively (Supplementary Fig. 1d–f).

### *Multivariant analysis*

Owing to the scarcity of events, a Cox regression analysis was conducted using two predictors: p16 status (categorized as positive or negative) and HIF-1α expression (classified as either high or low). The analysis revealed that overexpression of HIF-1α was significantly associated with poorer outcomes in OS, DFS, and LRRFS, with hazard ratios (HRs) of 1.6, 6.1, and 5.2, respectively. In contrast, tumors with positive p16 status exhibited a substantial improvement in OS (HR: 0.2), although the effects on DFS and LRRFS did not reach statistical significance (HRs: 0.36 and 0.28, respectively) (Table 2).

## Discussion

So far, studies examining the role of hypoxia in ASCC are limited. Lefèvre et al. previously investigated a 15-gene hypoxia classifier developed initially for head and neck squamous cell carcinoma in ASCC. However, they found no significant difference in locoregional control between more hypoxic and less hypoxic tumors [12].

As proof of concept, Bluemeke et al. showed dynamic tumor perfusion during the treatment in ASCC by comparing T1-weighted images before beginning the therapy and after the second week of treatment for patients breathing normal air or 100 % oxygen, indicating a possible dynamic of perfusion and hypoxia through the treatment [16].

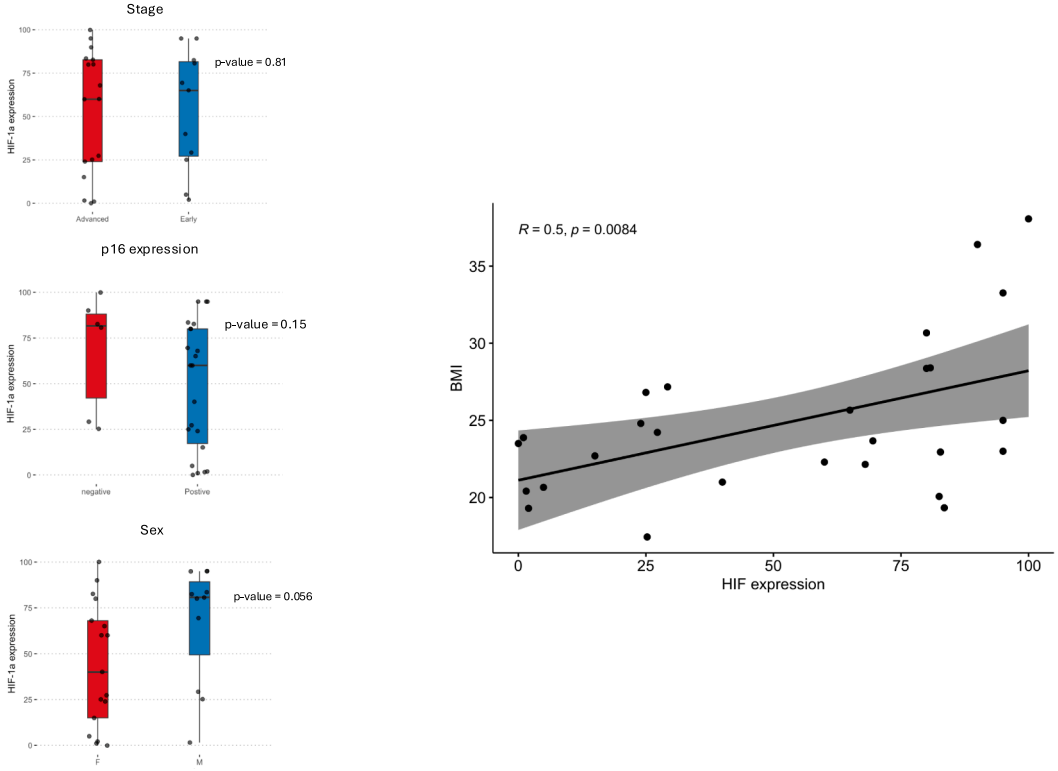


**Fig. 1.** Boxplots illustrate HIF-1α expression stratified by "a": cancer stage (early and advanced), "b": p16 status (positive and negative), and "c": Sex (F: Female and M: Male), scatter plot diagram "d" showing the Correlation between HIF-1α expression and body mass index (BMI).

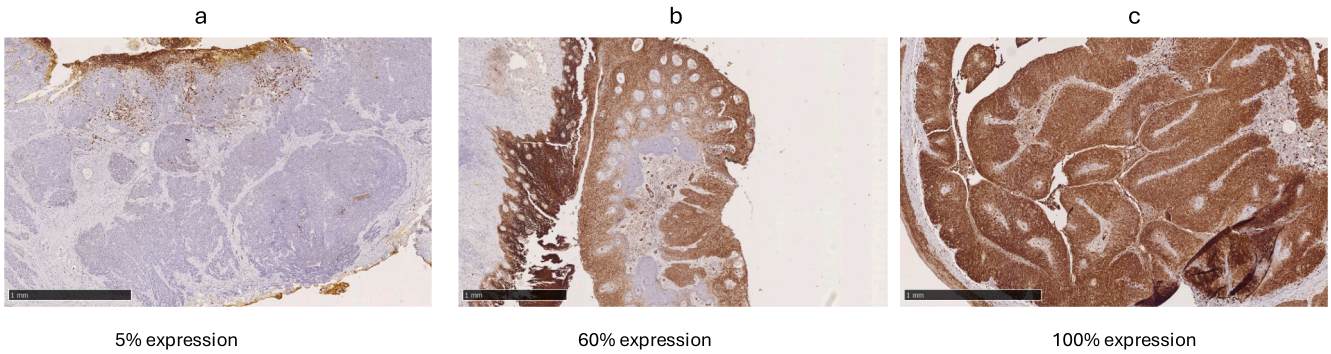


**Fig. 2.** Examples of HIF-1α Immunohistochemical staining from 3 patients with 5 %, 60 %, and 100 expressions, "a–c" respectively.

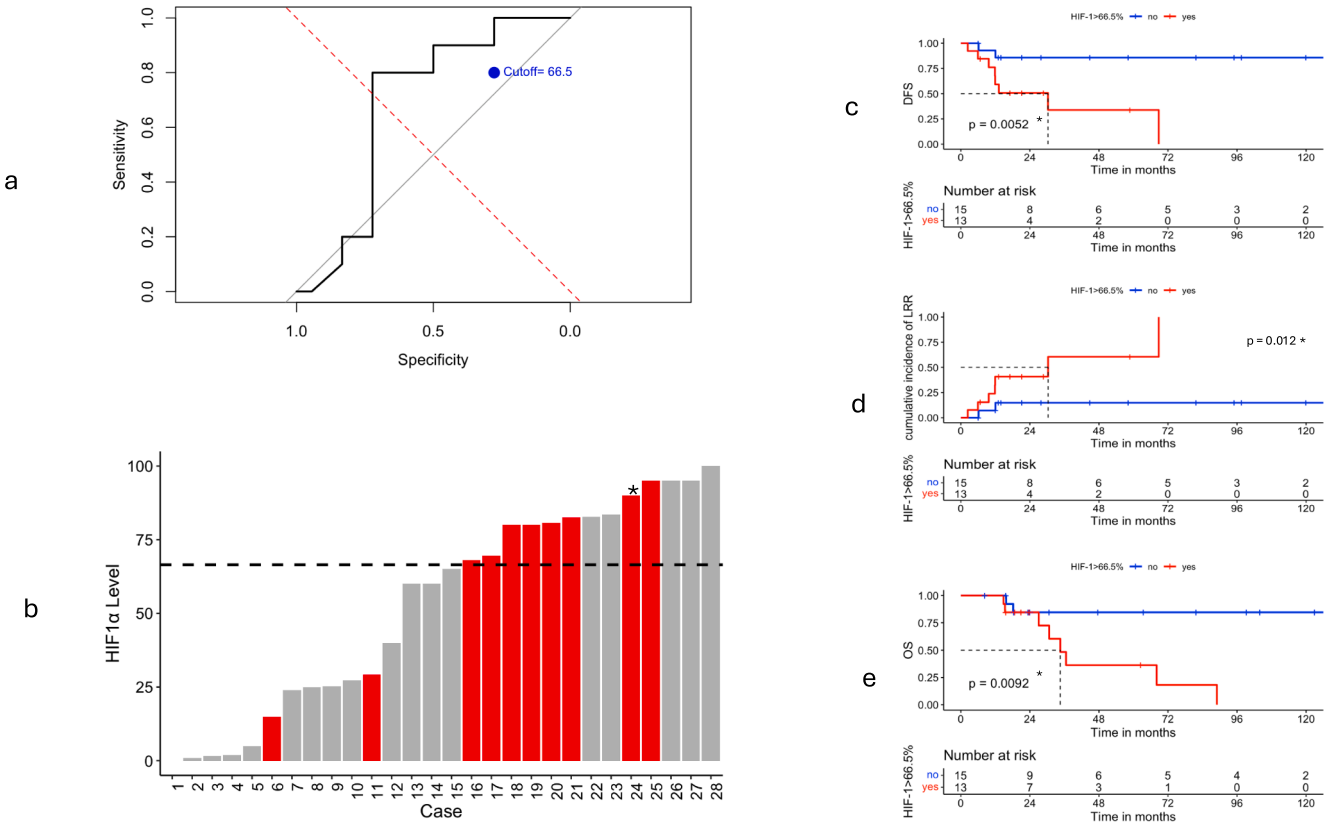


**Fig. 3.** "a" ROC analysis of HIF-1α expression, using disease-free survival (DFS) as the benchmark, identifies the optimal cutoff point at 62.5 %. "b": Histogram represents the distribution of HIF-1α levels across individual cases, with the dashed line indicating the established cutoff point at 62.5 %. Cases are ordered from lowest to highest expression levels of HIF-1α. The red bars signify cases with disease progression, and (*) signifies the patient with *PIK3CA* mutation. "c-e" Kaplan Meier curves show the difference for disease-free survival (DFS), the cumulative incidence of locoregional recurrence (LRR), and overall survival (OS), respectively, between low and high HIF-1α expression, * p-value < 0.05: statistically significant, log rank test.

**Table 2**
Univariate (log rank) and cox regression analyses, hr: hazard ratio, * p-value < 0.05: statistically significant.

| | Univariate analysis (Log rank): p-value | | | Cox regression: HR | | |
|---|---|---|---|---|---|---|
| | LRRFS | DFS | OS | LRRFS | DFS | OS |
| T1/2, N0 vs T3/4 and/or N1 | 0.63 | 0.77 | 0.5 | | | |
| p16-positive vs negative | 0.016* | 0.033* | 0.0038* | 0.28 | 0.36 | 0.2* |
| Low vs high HIF-1α expression | 0.012* | 0.005* | 0.009* | 5.2* | 6.1* | 1.6* |

HIF-1α plays a crucial role in the transcriptional regulation of key genes essential for tumor survival and advancement. Furthermore, HIF-1α is pivotal in modulating innate and adaptive immune responses and inflammation, establishing it as a significant transcriptional regulator of both immunity and inflammatory processes [17]. Its prognostic significance has been established in multiple cancer sites [18–22], but to the best of our knowledge, this has not been studied in ASCC.

The present study assessed the prognostic significance of HIF-1α expression in patients with ASCC undergoing curative RT/CRT, revealing a strong correlation between elevated HIF-1α levels and decreased survival rates across all parameters. These results highlight the potential of HIF-1α to serve as a valuable prognostic biomarker in ASCC. Remarkably, one case involved a female patient with a p16-

positive tumor and elevated HIF-1α expression (95 %), who experienced disease recurrence 69 months post-treatment, suggesting a potential dormancy for hypoxic tumors and the necessity for long follow-up for those patients.

The current study showed a marginally significant increased HIF-1α expression in males compared to females; this finding may contribute to the common phenomenon of improved outcomes in females compared to males in ASCC [13,23]. Further, there was no significant correlation between HIF-1α levels and tumor stage, p16 status, or age. However, we identified a positive correlation between BMI and HIF-1α expression levels. This finding may help explain our earlier observations linking higher BMI with poorer survival outcomes [14] and confirm the link between obesity and HIF-1 α expression previously described [24]. The mechanisms underlying the link between HIF-1α level and BMI is not well understood, but previous research has associated HIF-1α over-expression in tissues with obesity [28,29]. Given that BMI and obesity are modifiable risk factors, there is evidence about the role of physical activity, weight management, and lifestyle choices in altering cancer initiation and outcomes [25]. While the evidence in ASCC does not exist, numerous studies suggest that regular physical activity can lower the risk of developing various cancers, including those of the breast and prostate, by influencing metabolic and hormonal pathways [25–27].

Further, it is believed that hyperactivation of PI3K, leading to changes in the PI3K/AKT/mTOR signaling pathway, contributes to the development of cancer, especially in HPV-related cases [30–32]. The most frequent mutations activating this signaling pathway occur in the *PIK3CA* gene, which occurs in 10–25 % of ASCC [33,34] Also, PI3K/AKT activation could regulate the expression of HIF-1α [35]. However, in this analysis, an activating mutation in *PIK3CA* was identified in one patient (5.2 %), so a correlation with HIF-1α expression could not be established.

### *Limitation of the study*

The study presents several limitations that may affect the interpretation and generalizability of the findings. Firstly, the retrospective design inherently limits the ability to establish causality between HIF-1α expression levels and clinical outcomes. The study's reliance on archived FFPE tissue samples could also introduce variability in protein integrity, potentially influencing immunohistochemistry results. Another limitation arises from the sample size; although 28 patients were included in the final analysis, this number might still be too small to detect subtle associations or to ensure robust multivariate analysis results.

## Conclusion

This study has illuminated the prognostic significance of HIF-1α expression in ASCC patients treated with CRT, highlighting its potential as a biomarker for predicting treatment outcomes. High HIF-1α expression correlated with a heightened aggressive potential in ASCC, associated with poorer disease-free survival, locoregional relapse-free survival, and overall survival. These findings suggest that HIF-1α could be explored further as a prognostic factor in ASCC, potentially guiding the tailoring of management strategies (intensification for hypoxic tumors and de-escalation for normoxic ones). Future research should aim to validate these findings in larger, multicentric cohorts with longitudinal data to fully clarify the role of HIF-1α fully.

## Author contributions

Conception and design of the study (AMM, SW, ED), Data collection and analysis (AMM, SW, ED), Revision of the analysis (MJE, DJ), Manuscript drafting (AMM, SW, ED), critical revision of manuscript (MJE, DJ).

## Declaration of Generative AI and AI-assisted technologies in the writing process

During the preparation of this work, the authors used (Grammarly) to improve the manuscript's language and punctuation. After using this tool, the authors reviewed and edited the content as needed and take full responsibility for the content of the publication.

## Declaration of competing interest

The authors declare that they have no known competing financial interests or personal relationships that could have appeared to influence the work reported in this paper.

## Appendix A. Supplementary data

Supplementary data to this article can be found online at https://doi.org/10.1016/j.ctro.2024.100853.

## References

[1] Mignozzi S, Santucci C, Malvezzi M, Levi F, Vecchia C La, Negri E. Global trends in anal cancer incidence and mortality. 2023 [cited 2024 May 21]; Available from: www.eurjcancerprev.com.
[2] James RD, Glynne-Jones R, Meadows HM, Cunningham D, Myint AS, Saunders MP, et al. Mitomycin or cisplatin chemoradiation with or without maintenance chemotherapy for treatment of squamous-cell carcinoma of the anus (ACT II): a randomised, phase 3, open-label, 2×2 factorial trial. Lancet Oncol 2013;14(6):516–24.
[3] Kachnic LA, Winter K, Myerson RJ, Goodyear MD, Willins J, Esthappan J, et al. RTOG 0529: a phase II evaluation of dose-painted intensity modulated radiation therapy in combination with 5-fluorouracil and mitomycin-C for the reduction of acute morbidity in carcinoma of the anal canal. Int J Radiat Oncol Biol Phys 2013;86(1):27–33.
[4] Abhishek A, Kataria T, Gupta D, Basu T, Bisht S, Goyal S, et al. The development of an umbrella trial (PLATO) to address radiation therapy dose questions in the locoregional management of squamous cell carcinoma of the anus. Int J Radiat Oncol Biol Phys [Internet]. 2016 Oct 1 [cited 2022 Aug 10];96(2):E164–5. Available from: http://www.redjournal.org/article/S0360301616313323/fulltext.
[5] Li JZ, Gao W, Chan JYW, Ho WK, Wong TS. Hypoxia in head and neck squamous cell carcinoma. ISRN Otolaryngol 2012;16:1–8.
[6] Muz B, Puente P de la, Azab F, Azab AK. The role of hypoxia in cancer progression, angiogenesis, metastasis, and resistance to therapy. Hypoxia [Internet]. 2015 Dec [cited 2024 May 19];3:83. Available from: /pmc/articles/PMC5045092/.
[7] Li Y, Zhao L, Li XF. Hypoxia and the tumor microenvironment. Technol Cancer Res Treat [Internet]. 2021 Aug 5 [cited 2024 May 13];20. Available from: https://journals.sagepub.com/doi/10.1177/15330338211036304.
[8] Wang GL, Jiang BH, Rue EA, Semenza GL. Hypoxia-inducible factor 1 is a basic-helix-loop-helix-PAS heterodimer regulated by cellular O2 tension. Proc Natl Acad Sci U S A [Internet]. 1995 Jun 6 [cited 2024 May 1];92(12):5510. Available from: /pmc/articles/PMC41725/?report=abstract.
[9] Soni S, Padwad YS. Acta Oncologica HIF-1 in cancer therapy: two decade long story of a transcription factor HIF-1 in cancer therapy: two decade long story of a transcription factor. 2017 [cited 2024 Apr 25]; Available from: https://www.tandfonline.com/action/journalInformation?journalCode=ionc20.
[10] Jones CM, Goh V, Sebag-Montefiore D, Gilbert DC. Biomarkers in anal cancer: from biological understanding to stratified treatment. Br J Cancer [Internet]. 2017 Jan 1 [cited 2022 Aug 1];116(2):156. Available from: /pmc/articles/PMC5243987/.
[11] Theophanous S, Samuel R, Lilley J, Henry A, Sebag-Montefiore D, Gilbert A, et al. Prognostic factors for patients with anal cancer treated with conformal radiotherapy—a systematic review. BMC Cancer 2022 22:1 [Internet]. 2022 Jun 3 [cited 2022 Jun 29];22(1):1–12. Available from: https://bmccancer.biomedcentral.com/articles/10.1186/s12885-022-09729-4.
[12] Lefèvre AC, Alsner J, Sørensen BS, Tramm T, Toustrup K, Overgaard J, et al. Hypoxia and local tumour control in squamous cell carcinoma of the anus – a hypothesis-generating study. Acta Oncol (Madr) [Internet]. 2022 [cited 2024 May 13];61(9):1132–5. Available from: https://www.tandfonline.com/doi/abs/10.1080/0284186X.2022.2089591.
[13] Mohamed AA, Schlenter M, Heinzel A, Kintsler S, Eble M. Intensity-modulated radiotherapy associated with improved survival outcome in anal cancer. Front Oncol. 1AD;0:2566.
[14] Mohamed AA, Risse K, Stock J, Heinzel A, Mottaghy FM, Bruners P, et al. Body Composition as a Predictor of the Survival in Anal Cancer. Cancers 2022, Vol 14, Page 4521 [Internet]. 2022 Sep 18 [cited 2022 Sep 18];14(18):4521. Available from: https://www.mdpi.com/2072-6694/14/18/4521/htm.
[15] Rübben A, Wahl RU, Eggermann T, Dahl E, Ortiz-Brüchle N, Cacchi C. Mutation analysis of multiple pilomatricomas in a patient with myotonic dystrophy type 1 suggests a DM1-associated hypermutation phenotype. PLoS One [Internet]. 2020 [cited 2024 May 28];15(3). Available from: https://pubmed.ncbi.nlm.nih.gov/32155193/.

[16] Bluemke E, Bulte D, Bertrand A, George B, Cooke R, Chu KY, et al. Oxygen-enhanced MRI MOLLI T1 mapping during chemoradiotherapy in anal squamous cell carcinoma. May 1 [cited 2024 May 19];22:44–9. Available from: Clin Transl Radiat Oncol [internet] 2020. http://www.ctro.science/article/S2405630820300148/fulltext.

[17] Bui BP, Nguyen PL, Lee K, Cho J. Hypoxia-inducible factor-1: a novel therapeutic target for the management of cancer, drug resistance, and cancer-related pain. Cancers (Basel) [Internet]. 2022 Dec 1 [cited 2024 May 19];14(24). Available from: /pmc/articles/PMC9775408/.

[18] Chen B, Li L, Li M, Wang X. HIF1A expression correlates with increased tumor immune and stromal signatures and aggressive phenotypes in human cancers. Cell Oncol (Dordr) [Internet]. 2020 Oct 1 [cited 2024 May 19];43(5):877–88. Available from: https://pubmed.ncbi.nlm.nih.gov/32488852/.

[19] Hoffmann AC, Mori R, Vallbohmer D, Brabender J, Klein E, Drebber U, et al. High expression of HIF1a is a predictor of clinical outcome in patients with pancreatic ductal adenocarcinomas and correlated to PDGFA, VEGF, and bFGF. Neoplasia 2008;10(7):674–9.

[20] Baba Y, Nosho K, Shima K, Irahara N, Chan AT, Meyerhardt JA, et al. HIF1A overexpression is associated with poor prognosis in a cohort of 731 colorectal cancers. Am J Pathol 2010;176(5):2292–301.

[21] Eckert AW, Kappler M, Große I, Wickenhauser C, Seliger B. Current Understanding of the HIF-1-Dependent Metabolism in Oral Squamous Cell Carcinoma. International Journal of Molecular Sciences 2020, Vol 21, Page 6083 [Internet]. 2020 Aug 24 [cited 2024 May 19];21(17):6083. Available from: https://www.mdpi.com/1422-0067/21/17/6083/htm.

[22] dos Santos M, da C. Mercante AM, Louro ID, Gonçalves AJ, de Carvalho MB, da Silva EHT, et al. HIF1-alpha expression predicts survival of patients with squamous cell carcinoma of the oral cavity. Sep 18 [cited 2024 May 19];7(9). Available from: PLoS One [internet] 2012. https://pubmed.ncbi.nlm.nih.gov/23028863/.

[23] Holliday EB, Morris VK, Johnson B, Eng C, Ludmir EB, Das P, et al. Definitive intensity-modulated chemoradiation for anal squamous cell carcinoma: outcomes and toxicity of 428 patients treated at a single institution. Oncologist [Internet]. 2022 Jan 1 [cited 2024 Aug 27];27(1):40. Available from: /pmc/articles/PMC8842324/.

[24] Norouzirad R, González-Muniesa P, Ghasemi A. Hypoxia in obesity and diabetes: potential therapeutic effects of hyperoxia and nitrate. Oxid Med Cell Longev [Internet]. 2017 [cited 2022 Jul 30];2017. Available from: /pmc/articles/PMC5457776/.

[25] Sharman R, Harris Z, Ernst B, Mussallem D, Larsen A, Gowin K. Lifestyle factors and cancer: a narrative review. Mayo Clin Proc Innov Qual Outcomes 2024;8(2):166–83.

[26] Cariolou M, Abar L, Aune D, Balducci K, Becerra-Tomás N, Greenwood DC, et al. Postdiagnosis recreational physical activity and breast cancer prognosis: Global Cancer Update Programme (CUP Global) systematic literature review and meta-analysis. Int J Cancer [Internet]. 2023 Feb 2 [cited 2024 Aug 27];152(4):600. Available from: /pmc/articles/PMC10091720/.

[27] Giovannucci EL, Liu Y, Leitzmann MF, Stampfer MJ, Willett WC. A prospective study of physical activity and incident and fatal prostate cancer. Arch Intern Med [Internet]. 2005 May 9 [cited 2024 Aug 27];165(9):1005–10. Available from: https://jamanetwork.com/journals/jamainternalmedicine/fullarticle/1152790.

[28] He Q, Gao Z, Yin J, Zhang J, Yun Z, Ye J. Regulation of HIF-1α activity in adipose tissue by obesity-associated factors: adipogenesis, insulin, and hypoxia. Am J Physiol Endocrinol Metab [Internet]. 2011 May [cited 2024 May 19];300(5):877–85. Available from: http://www.ajpendo.org.

[29] Adesunloye BA. Mechanistic Insights into the Link between Obesity and Prostate Cancer. Int J Mol Sci 2021, Vol 22, Page 3935 [Internet]. 2021 Apr 11 [cited 2024 May 19];22(8):3935. Available from: https://www.mdpi.com/1422-0067/22/8/3935/htm.

[30] Koncar RF, Feldman R, Bahassi EM, Hashemi Sadraei N. Comparative molecular profiling of HPV-induced squamous cell carcinomas. Cancer Med [Internet]. 2017 Jul 1 [cited 2024 May 19];6(7):1673–85. Available from: https://pubmed.ncbi.nlm.nih.gov/28556593/.

[31] Ma YY, Wei SJ, Lin YC, Lung JC, Chang TC, Whang-Peng J, et al. PIK3CA as an oncogene in cervical cancer. Oncogene [Internet]. 2000 May 25 [cited 2024 May 19];19(23):2739–44. Available from: https://pubmed.ncbi.nlm.nih.gov/10851074/.

[32] Shin MK, Payne S, Bilger A, Matkowskyj KA, Carchman E, Meyer DS, et al. Activating mutations in Pik3ca contribute to anal carcinogenesis in the presence or absence of HPV-16 oncogenes. Clin Cancer Res [Internet]. 2019 Mar 3 [cited 2024 May 19];25(6):1889. Available from: /pmc/articles/PMC6423984/.

[33] Cacheux W, Rouleau E, Briaux A, Tsantoulis P, Mariani P, Richard-Molard M, et al. Mutational analysis of anal cancers demonstrates frequent PIK3CA mutations associated with poor outcome after salvage abdominoperineal resection. Br J Cancer [Internet]. 2016 Jun 6 [cited 2024 May 19];114(12):1387. Available from: /pmc/articles/PMC4984471/.

[34] Morris V, Rao X, Pickering C, Foo WC, Rashid A, Eterovic K, et al. Comprehensive genomic profiling of metastatic squamous cell carcinoma of the anal canal. Molecular Cancer Research [Internet]. 2017 Nov 1 [cited 2024 May 19];15(11):1542–50. Available from: /mcr/article/15/11/1542/89718/Comprehensive-Genomic-Profiling-of-Metastatic.

[35] Zhang Z, Yao L, Yang J, Wang Z, Du G. PI3K/Akt and HIF–1 signaling pathway in hypoxia–ischemia (Review). Mol Med Rep [Internet]. 2018 Oct 1 [cited 2024 May 19];18(4):3547–54. Available from: https://pubmed.ncbi.nlm.nih.gov/30106145/.